

# Oncology Emergency Modules: Spinal Cord Compression

Jo Ann Flounders, RN, MSN, OCN®, CHPN, and Barbara B. Ott, RN, PhD

**S**pinal cord compression (SCC) is compression of the thecal sac by a tumor in the epidural space, either at the level of the spinal cord or cauda equina (Quinn & DeAngelis, 2000). Because SCC can cause direct injury to the spinal cord, it requires prompt intervention to prevent progressive and irreversible neurologic disability (Bucholtz, 1999; Quinn & DeAngelis; Wilkes, 1999).

## Etiology

SCC occurs as a result of a malignant neoplasm compressing the spinal cord. Malignant tumors may be classified as primary (i.e., arising from the tissue of the spinal cord or spinal canal) or secondary (i.e., arising as metastatic solid tumors) (Schafer, 1997). SCC most commonly is caused by metastatic tumors. Progression of symptoms is more rapid with metastatic tumors when compared to primary spinal cord tumors (Wilkes, 1999). The most frequent types of primary malignancies causing skeletal metastasis are lung, breast, and prostate, followed by lymphoma, myeloma, and renal carcinoma (Schafer, 1997). The location of the metastatic lesion in the spine correlates with the type of primary malignancy. Cervical spine lesions often are caused by primary breast tumors; thoracic spine lesions often are caused by primary lung, breast, and prostate tumors; and lumbosacral spine lesions often are caused by gastrointestinal and prostate malignancies (Wilkes). The most frequent site of metastasis that causes SCC is the thoracic area of the spinal column.

Paraneoplastic syndromes, carcinomatous myelopathy, radiation myelopathy, herpes zoster, retroperitoneal tumor, or toxicity of cytotoxic medications also may cause spinal cord syndromes. Other causes include nonmalignant conditions in patients with cancer, such as herniated disks, vertebral fractures secondary to osteoporosis, and intraspinal abscesses (DeMichele & Glick, 2001).

## Pathophysiology

The vertebral column contains 26 vertebrae: 7 cervical, 12 thoracic, 5 lumbar, 1 sacral, and 1 coccygeal (Schafer, 1997).

The spinal cord, an elongated mass of nervous tissue, is located in the flexible vertebral column. The spinal cord arises from the medulla oblongata in the brain, begins at the foramen magnum, and extends to the lower aspect of the first lumbar (L1) vertebra (Belford, 1997). Because the spinal cord ends at L1–L2, the lumbar and sacral nerves exit the cord there (Wilkes, 1999). Because the spinal cord is approximately 10 inches shorter than the vertebral column, the lumbar and sacral spinal nerves have long roots that extend from the distal tip of the spine to the lumbar and sacral areas. These roots are known as the cauda equina because of their resemblance to a horse's tail (Belford).

The effects of compression of the spinal cord range from minor sensory, motor, and autonomic changes to severe pain and complete paralysis (Hunter, 1998). Thirty-one pairs of spinal nerves exit from the spinal cord. Sensory or afferent

---

### Goal for CE Enrollees:

To further enhance nurses' knowledge regarding spinal cord compression.

### Objectives for CE Enrollees:

- On completion of this CE, the participant will be able to
1. Describe the pathophysiologic process of spinal cord compression.
  2. Discuss the diagnosis and treatment of patients with spinal cord compression.
  3. Discuss the nursing implications in the care of patients with spinal cord compression.

---

*Jo Ann Flounders, RN, MSN, OCN®, CHPN, is a nurse practitioner at Consultants in Medical Oncology and Hematology in Drexel Hill, PA, and Barbara B. Ott, RN, PhD, is an associate professor in the College of Nursing at Villanova University in Pennsylvania.*

Digital Object Identifier: 10.1188/03.ONF.E17-E23

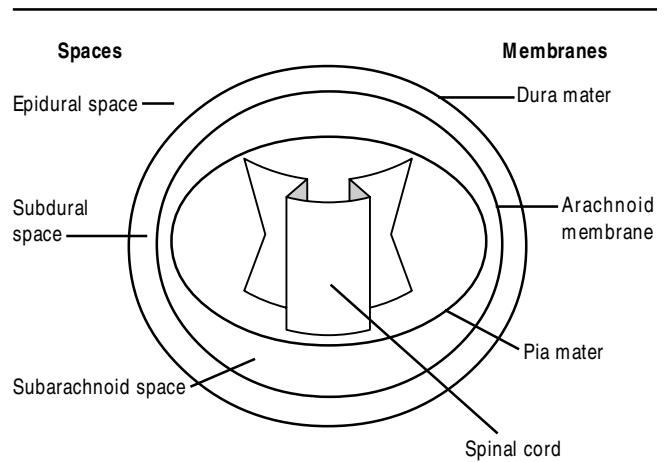
impulses enter the spinal cord through a dorsal root of each spinal nerve and convey sensory information from the body to the spinal cord. Motor or efferent impulses, including autonomic impulses, leave the spinal cord through a ventral root of a spinal nerve and convey impulses from the spinal cord back to the body (Belford, 1997). Transmission of impulses to and from the brain and spinal cord occurs in the ascending and descending tracts, which extend the length of the spinal cord. Impulses from the spinal cord to the brain are transmitted through the anterior spinothalamic tracts, and impulses from the brain to the spinal cord are transmitted through the lateral corticospinal tract (Henze, 2000). Therefore, injury to the spinal nerves or the spinal cord can result in sensory-motor and autonomic impairment (Wilkes, 1999).

Three membranes, or meninges (see Figure 1), that originate in the brain and extend downward over the spinal cord are layered to protect the brain and the spinal cord (Schafer, 1997; Wilkes, 1999). The outermost layer is the dura mater, under which is the arachnoid membrane, followed by the innermost membrane, the pia mater, which is connected closely to the spinal cord. Between the meninges and adjacent structures are the epidural or extradural space, located between the vertebral column and the outer surface of the dura mater; the subdural space, located between the dura membrane and the arachnoid membrane; and the subarachnoid space, located between the arachnoid membrane and the pia mater. The subarachnoid space contains cerebrospinal fluid (CSF) (Schafer, 1997).

The malignant invasion of the spinal cord that causes SCC can occur at several possible anatomic locations (Wilkes, 1999). The most common location is extradural, caused when a tumor arises outside the spinal cord, as in bony metastasis to the vertebrae. These extradural metastatic tumors can be osteolytic or osteoblastic (Bucholtz, 1999; Byrne, 1997; Schafer, 1997). Osteolytic lesions invade the vertebrae and cause bone destruction when tumor cells stimulate osteoclasts to absorb bony tissue. In contrast, osteoblastic lesions occur when tumor cells stimulate osteoblasts to develop into bone (Schafer, 1997). The tumor invades and destroys the vertebral body, causes vertebral collapse, and compresses the spinal cord as tumor or bone particles are pushed into the epidural space (Wilkes).

In addition to extradural tumors, other locations for malignant invasion of the spinal cord exist. Intramedullary tumors are primary tumors that develop in the spinal cord itself. Intradural tumors arise from the coverings of the spinal cord or from the nerve roots and are located in the dura. Extravertebral tumors originate outside the vertebrae and extend into the epidural space by extending between the vertebrae and pushing through the intervertebral foramina (Belford, 1997; Wilkes, 1999).

Several mechanisms may facilitate metastasis to the epidural space (Belford, 1997; Bucholtz, 1999; Schafer, 1997). The most common mechanism is through hematogenous spread as an embolic process from the primary site through the paravertebral and extradural venous plexus to bone marrow, which causes vertebral body collapse and an epidural mass. In addition, adenopathy of the prevertebral lymph nodes can cause growth into the epidural space, as in lymphoma (Schafer, 1997). Seeding of the CSF may occur with cancers of the central nervous system, which can lead to subsequent spreading to the subarachnoid space and seeding along the brain and spinal cord (Belford).



**Figure 1. Meninges or Membranes Surrounding the Spinal Cord, With Associated Spaces**

The neurologic deficits caused by SCC result from one of the following processes. The tumor directly compresses the spinal cord or cauda equina; the tumor or bone interrupts the vascular supply to the nerve structure; or a pathologic fracture causes a vertebral collapse that causes bone to protrude onto the spinal cord and compress the nerve roots (Schafer, 1997).

The pressure from a growing tumor can cause a series of reactions leading to nerve tissue injury. Compression of the epidural venous plexus causes vasogenic edema and the production of cytokines, such as interleukin-1, interleukin-6, and prostaglandin. Vasodilation occurs, as well as plasma exudation and edema, causing injury to nerve tissue. Additional nerve tissue injury is caused by the neurotransmitters serotonin and glutamide. Cytotoxic edema, leading to cell death and irreversible paraplegia, occurs (Bucholtz, 1999).

## Identification of Patients at Risk

The risk of development of SCC for patients with cancer corresponds to the etiologic factors that cause SCC. Patients at risk for developing SCC include those with cancers that commonly metastasize to the bone, such as breast, lung, prostate, renal, and myeloma; patients with cancers that metastasize to the spinal cord, such as lymphoma, seminoma, and neuroblastoma; and patients with primary tumors of the spinal cord, such as ependymoma, astrocytoma, and glioma (Hunter, 1998; Schafer, 1997; Wilkes, 1999).

## Assessment

### Review of Systems

The clinical manifestations of SCC correspond to the site and extent of malignant invasion of the vertebral cord (Bucholtz, 1999; Schafer, 1997). Cardinal signs include pain and sensory, motor, and autonomic dysfunction (Schafer, 1997).

Neck or back pain is the most common presenting symptom of SCC (Byrne, 1997; DeMichele & Glick, 2001; Dietz & Flaherty, 1993; Siegal & Siegel, 1989; Wilkes, 1999). Pain can precede the actual compression of the spinal cord, as well as any neurologic signs and symptoms (Bucholtz, 1999; DeMichele & Glick). Pain can be localized or radicular. Local-

ized pain occurs in the area of the tumor (Wilkes); is described as constant, dull, and aching (Hunter, 1998); and is caused by an expanding blastic or lytic lesion within the vertebral body (Bucholtz). The malignant lesion can stretch the periosteum of the affected bone or cause vertebral collapse, resulting in localized pain (Schafer, 1997).

As tumor growth advances, the nerve root becomes compressed and pain becomes radicular with shooting or burning intensity. Radicular pain is described as radiating along the dermatome of the affected nerve roots. Pain secondary to cervical and lumbosacral involvement usually is unilateral, and thoracic radicular pain is bilateral and described by patients as a tight band across the chest or abdomen. Radicular pain may be constant or aggravated by movement, such as coughing, sneezing, the Valsalva maneuver (i.e., increasing nasopharyngeal pressure by straining against a closed glottis), or the supine recumbent position and may be relieved by sitting (Dietz & Flaherty, 1993; Schafer, 1991, 1997; Wilkes, 1999). An important distinction is that pain resulting from SCC may be relieved by the sitting position and is not relieved, and actually may increase, when patients assume the supine position. The opposite is true for pain secondary to a herniated disk (Schafer, 1991, 1997; Wilkes). Patients with SCC may complain that pain increases at night when lying down to sleep, which is the opposite pattern from degenerative spine disease (Quinn & DeAngelis, 2000).

Patients with preexisting skeletal bone metastasis are at increased risk for SCC. Because these patients often experience chronic back pain secondary to metastasis, early detection of the signs of SCC may be difficult. Any change in the intensity, location, or nature of a patient's pain can be an early sign of SCC and requires careful and complete assessment (Dietz & Flaherty, 1993).

As the lytic and blastic lesions protrude into the epidural space, neurologic symptoms occur and may become irreversible. The earliest neurologic manifestations include motor weakness and sensory loss related to the level and degree of SCC (Bucholtz, 1999; Dietz & Flaherty, 1993; Wilkes, 1999). Motor weakness usually is not the presenting symptom, as the development of pain usually precedes motor weakness. The sequence of neurologic symptoms as SCC progresses is pain, motor weakness, sensory loss, motor loss, and autonomic dysfunction (Schafer, 1997).

Motor weakness often is described as heaviness or stiffness of the extremities and may lead to loss of coordination and ataxia. If SCC is untreated, motor weakness will progress to motor loss and paralysis. Sensory loss includes numbness, paresthesia, and loss of thermal sensation, and progressive sensory loss includes loss of proprioception and deep pressure and vibration sensations (DeMichele & Glick, 2001; Dietz & Flaherty, 1993; Schafer, 1997; Wilkes, 1999). Sensory dysfunction usually begins in the toes and ascends as it reaches the level of the lesion. With cauda equina compression, the sensory loss is bilateral and usually follows the dermatome path involving the perianal area, posterior thigh, and lateral aspect of the leg (Quinn & DeAngelis, 2000).

Autonomic dysfunction is common, generally late, and never the sole presenting symptom of epidural SCC (Posner, 1995; Quinn & DeAngelis, 2000). However, these symptoms may occur early with cauda equina syndrome. Signs of autonomic dysfunction include impotence and changes in bladder and bowel function. Possible urinary symptoms include hesitancy,

retention, overflow, and incontinence. Bowel dysfunction includes lack of urge to defecate and lack of ability to bear down, with resultant constipation or obstipation. A late sign of autonomic dysfunction is loss of sphincter control, a sign associated with a poorer prognosis (DeMichele & Glick, 2001; Dietz & Flaherty, 1993; Schafer, 1991, 1997; Wilkes, 1999).

## Physical Examination

The importance of thorough assessment of neck and back pain in patients with cancer cannot be overemphasized. Patients who present only with localized back pain and a normal neurologic examination may have a greater than 75% block of the spinal cord (Dietz & Flaherty, 1993). The single critical prognostic factor in SCC is neurologic status before the initiation of therapy (Dietz & Flaherty). Therefore, because ambulatory status at the time of diagnosis is predictive of a patient's ability to ambulate after treatment, early detection and prompt treatment of SCC is necessary to prevent irreversible neurologic dysfunction and preserve ambulatory function (Wilkes, 1999).

A thorough history should be obtained with special attention to intensity, quality, onset, and duration of symptoms (Hunter, 1998). Patients should be questioned regarding symptoms of motor weakness, sensory loss, motor loss, and autonomic dysfunction. Clinicians should ask patients about sexual function and changes in bowel and bladder function, including incontinence and loss of sphincter control (Bucholtz, 1999). Even if back pain is the only symptom, clinicians should suspect SCC in patients with cancer until otherwise disproved (Wilkes, 1999).

A thorough physical examination should be completed with special attention to musculoskeletal and neurologic systems. Vertebral palpation and percussion by the examiner usually can elicit patient complaints of radicular pain or tenderness at the level of compression (Bucholtz, 1999; DeMichele & Glick, 2001; Schafer, 1997). Straight leg raises usually will increase pain when radicular pain is present (Schafer, 1997). Examiners should raise a patient's straightened leg until pain occurs, then dorsiflex the foot. Sharp pain radiating from the back down the leg, with increased pain on dorsiflexion, suggests compression of the nerve roots (Bickley, 1999). Assessment of motor function also includes evaluation of gait, muscle strength, involuntary movements, and coordination (Wilkes, 1999).

Assessment of reflexes is an important indication of the status of the central nervous system. A brisk reflex response should be elicited normally, which indicates that the arc, or pathway, from the receptor organ to the spinal cord and back to the effector organ is intact (Wilkes, 1999). Deep tendon reflexes may be decreased with nerve root compression and hyperactive with cord compression. A positive Babinski sign (i.e., dorsiflexion of the great toe after stroking the sole of the foot from heel to the ball of the foot and then laterally continuing across the ball of the foot to under the great toe) or sustained ankle clonus also indicate motor involvement (Schafer, 1997). Physical examination should include assessment of sensory function such as pain, temperature, touch, vibration, and position (Bickley, 1999). The location of sensory loss helps to pinpoint the site of sensory damage (Wilkes). Examiners should perform meticulous sensory mapping to elicit the level of SCC (Bucholtz, 1999). Usually the level of positive sensation is one or two levels below the site of compression (DeMichele & Glick, 2001).

## Diagnostic Studies

X-ray films of the spine are initial diagnostic tests for SCC. These films will show lytic or blastic lesions and can identify up to 85% of vertebral lesions. However, these x-rays cannot detect early SCC, because 50% of the bone must be destroyed before the lesions can be detected on x-ray films (Bucholtz, 1999). Another problem with x-ray films, significant in lung cancer and lymphoma, is that paraspinal masses with extension into the epidural space through the foramina may not be detected (Schafer, 1997). Bone scans are more sensitive than x-rays and may detect vertebral abnormalities when x-ray films are negative (Bucholtz).

Magnetic resonance imaging (MRI), computerized tomography (CT), and myelography are definitive diagnostic tests for SCC (Bucholtz, 1999; DeMichele & Glick, 2001; Wilkes, 1999). MRI is superior to CT scans and myelography because MRI is noninvasive and does not require the injection of contrast material. However, the addition of gadolinium contrast with MRI improves detection of disease. Another benefit of MRI is that it can image the entire spine, a necessary function because patients may have multiple areas of compression that are not clinically apparent (Bucholtz). CT scanning with IV contrast allows identification of paraspinal masses and early lesions not seen on x-ray films but does not image the entire spine (Schafer, 1997; Wilkes). Myelography commonly has been replaced by MRI but can be used when MRI is nondiagnostic or cannot be completed (Wilkes). Lumbar puncture may be performed to examine the CSF but is not diagnostic of SCC. Elevation of CSF proteins to levels greater than 100 mg/ml has been noted in most patients with SCC (DeMichele & Glick). Positron emission tomography can complement the information obtained from MRI or CT (Belford, 1997).

## Medical Management

Corticosteroids, radiation therapy, and surgery are the standard treatment options for patients with SCC (Belford, 1997; Bucholtz, 1999; DeMichele & Glick, 2001; Hunter, 1998; Posner, 1990; Quinn & DeAngelis, 2000; Schafer, 1997; Wilkes, 1999). The goals of treatment are pain relief and preservation and restoration of neurologic function (Bucholtz), as well as reduction of tumor bulk. Treatment of SCC often is palliative in intent because it usually is associated with other metastatic disease (Quinn & DeAngelis). Treatment of the underlying primary cancer must be reevaluated. The choice of treatment for SCC depends on the tumor type, location, aggressiveness, and radiosensitivity (Bucholtz, 1999). In addition, effective pain management may require titration of narcotic analgesia.

Corticosteroid therapy usually is the initial treatment of SCC until more definitive treatment, such as radiation therapy or surgery, can be instituted (Quinn & DeAngelis, 2000). Corticosteroids are used to decrease spinal cord edema and inflammation, which can relieve pain and neurologic symptoms (Wilkes, 1999). Corticosteroids also may have an oncolytic effect on some tumors (Hunter, 1998). A schedule for corticosteroid administration often includes a loading dose of high-dose dexamethasone (100 mg) followed by tapering doses over a period of days (Belford, 1997; Posner, 1990). Corticosteroids can cause gastrointestinal bleeding, hyperglycemia, psychosis, myopathy, os-

teoporosis, and acute adrenal insufficiency with abrupt steroid withdrawal (Belford).

Radiation therapy is the most common treatment for SCC (Bucholtz, 1999; Hunter, 1998; Quinn & DeAngelis, 2000). Radiation therapy is delivered over several weeks to a total dose of 3,000–4,000 cGy (Hunter). The radiation treatment field usually covers the area of the SCC as well as a margin of one or two vertebral bodies above and below the area of compression (Bucholtz; Loblaw & Laperriere, 1998). Radiation therapy can result in improvement or maintenance of functional status and relief of pain, which usually occurs up to five days after treatment is initiated (Bucholtz). Side effects of radiation therapy include fatigue and skin alterations, including erythema, pigmentation, and dry or moist desquamation. Goals of managing the side effects of radiation therapy include minimizing symptoms, promoting healing, and preventing infections (Sitton, 1997).

Many indications for surgical decompression by laminectomy or resection of a vertebral body exist. Surgery is considered when tumors are not radiosensitive or located in an area that has been previously treated with radiation therapy (Hunter, 1998). Surgery also is beneficial in obtaining a tumor specimen to establish a tissue diagnosis in patients with no known primary site of malignancy (Bucholtz, 1999). Surgery is necessary if infection or epidural hematoma must be ruled out or if high cervical spinal cord lesions are present that can cause respiratory paralysis without prompt treatment (DeMichele & Glick, 2001). A surgical approach is beneficial with spinal instability or when neurologic deterioration progresses despite ongoing radiation therapy (Schafer, 1997). Potential complications related to surgery include standard postoperative risks (e.g., stroke, hematoma, deep vein thrombosis, pulmonary embolism, wound dehiscence), CSF leak, or neurologic deficits (Belford, 1997).


## Nursing Management

Through accurate assessment of pain and musculoskeletal and neurologic changes, oncology nurses can detect the early signs of SCC and provide interventions to prevent neurologic dysfunction (Bucholtz, 1999). Accurate pain and neurologic assessment should be the standard of care for all patients on a routine basis, allowing subtle changes in patient status to be detected early. In addition, oncology nurses should provide pharmacologic and nonpharmacologic interventions to relieve pain. Nurses should provide interventions to prevent complications from immobility and sensory-motor deficits, including attention to bladder and bowel function (Wilkes, 1999). Nurses should assess patients for complications of SCC treatment. Assessment and interventions for inadequate coping and potential depression should be included in the plan of care. Discharge planning should include consideration of referral for home visiting nurses or hospice care as needed.

*The authors would like to thank John Sprandio, MD, of Consultants in Medical Oncology and Hematology, Drexel Hill, PA, for reviewing this manuscript.*

**Author Contact:** Jo Ann Flounders, RN, MSN, OCN®, CHPN, can be reached at joann@theflounders.com, with copy to editor at rose\_mary@earthlink.net.

## References

- Belford, K. (1997). Central nervous system cancers. In S. Groenwald, M. Frogge, M. Goodman, & C. Yarbrow (Eds.), *Cancer nursing* (4th ed., pp. 721–741). Boston: Jones and Bartlett.
- Bickley, L. (1999). *Bates' guide to physical examination and history taking* (7th ed.). Philadelphia: Lippincott.
- Bucholtz, J. (1999). Metastatic epidural spinal cord compression. *Seminars in Oncology Nursing*, 15, 150–159.
- Byrne, T. N. (1997). Metastatic epidural spinal cord compression. In P. Black & J. Loeffler (Eds.), *Cancer of the nervous system* (pp. 664–673). London: Blackwell Scientific.
- DeMichele, A., & Glick, J. (2001). Cancer-related emergencies. In R. Lenhard, R. Osteen, & T. Gansler (Eds.), *Clinical oncology* (pp. 733–764). Atlanta, GA: American Cancer Society.
- Dietz, K., & Flaherty, A. (1993). Oncologic emergencies. In S. Groenwald, M. Frogge, M. Goodman, & C. Yarbrow (Eds.), *Cancer nursing* (3rd ed., pp. 800–839). Boston: Jones and Bartlett.
- Henze, R. (2000). Traumatic and vascular injuries of the central nervous system. In B. Bullock & R. Henze (Eds.), *Focus on pathophysiology* (pp. 938–978). Philadelphia: Lippincott.
- Hunter, J. (1998). Structural emergencies. In J. Itano & K. Taoka (Eds.), *Core curriculum for oncology nursing* (3rd ed., pp. 340–354). Philadelphia: Saunders.
- Loblaw, D., & Laperriere, N. (1998). Emergency treatment of malignant extradural spinal cord compression: An evidence-based guideline. *Journal of Clinical Oncology*, 16, 1613–1624.
- Posner, J. (1990). Surgery for metastasis to the brain. *New England Journal of Medicine*, 322, 544–545.
- Posner, J. (1995). *Neurologic complications of cancer*. Philadelphia: Davis.
- Quinn, J., & DeAngelis, L. (2000). Neurologic emergencies in the cancer patient. *Seminars in Oncology*, 27, 311–321.
- Schafer, S. (1991). Oncologic complications: Spinal cord compression. In S. Otto (Ed.), *Oncology nursing* (pp. 468–526). St. Louis, MO: Mosby Year Book.
- Schafer, S. (1997). Oncologic complications. In S. Otto (Ed.), *Oncology nursing* (3rd ed., pp. 406–474). St. Louis, MO: Mosby Year Book.
- Siegel, T.A., & Siegel, T.E. (1989). Current considerations in the management of neoplastic spinal cord compression. *Spine*, 14, 223–228.
- Sitton, E. (1997). Managing side effects of skin changes and fatigue. In K. Dow, J. Bucholtz, R. Iwamoto, V. Fieler, & L. Hilderley (Eds.), *Nursing care in radiation oncology* (2nd ed., pp. 79–100). Philadelphia: Saunders.
- Wilkes, G. (1999). Neurological disturbances. In C. Yarbrow, M. Frogge, & M. Goodman (Eds.), *Cancer symptom management* (2nd ed., pp. 344–381). Boston: Jones and Bartlett. 

---

### For more information . . .

- ▶ *Merck Manual: Spinal Cord Disorders*  
[www.merck.com/pubs/mmanual/section14/chapter182/182b.htm](http://www.merck.com/pubs/mmanual/section14/chapter182/182b.htm)
- ▶ *Surgical Tutor: Spinal Cord Compression*  
[www.surgical-tutor.org.uk/system/locomotor/cord\\_compression.htm](http://www.surgical-tutor.org.uk/system/locomotor/cord_compression.htm)

*Links can be found using ONS Online at [www.ons.org](http://www.ons.org).*

---