

The Pathogenesis and Characterization of Oral Mucositis Associated With Cancer Therapy

Marylin J. Dodd, RN, PhD, FAAN

Purpose/Objectives: To describe the current knowledge about the pathogenesis of oral mucositis associated with cancer therapy and oral mucositis.

Data Sources: Published research and literature review articles, books, and posters of findings that have been selected for presentation at research conferences.

Data Synthesis: Aggressive cancer treatment yields gains in cure or sustained control but also in oral complications, including oral mucositis. Recent work suggests that oral mucositis involves a series of biologically and physiologically complex cellular and tissue interactions that vary in accordance with treatment type and characteristics.

Conclusions: The impact of treatment-related oral mucositis in patients is multifaceted and can significantly affect patients' experiences in terms of morbidity and treatment course. The creation of effective, targeted management strategies ultimately relies on a better understanding of the biologic processes underlying oral mucositis development coupled with systematic use of assessment tools.

Implications for Nursing: Incorporating current knowledge about the pathogenesis of oral mucositis with regular use of available assessment instruments can help to ensure prompt recognition of oral manifestations and facilitate better treatment strategies.

Oral mucositis is an acute, painful, and often dose-limiting toxicity experienced by the majority of patients who receive stomatotoxic chemotherapy or head and neck radiation therapy or undergo blood and marrow stem cell transplant (BMSCT). Its incidence, which varies by patient diagnosis, age, level of oral health, and type, dose, and frequency of drug administration (Pico, Avila-Garavito, & Naccache, 1998) ranges from 40% among patients receiving chemotherapy to 100% among patients undergoing head and neck therapy to fields involving the oral cavity (National Cancer Institute [NCI], 2003). The impact of oral mucositis is multifaceted and substantial, ranging from interference with activities of daily living, interruptions in therapy, and increased risk for subsequent treatment failure to systemic infections, hospitalizations, and, rarely, death. Yet, despite its high prevalence and clinical significance, the pathogenesis of oral mucositis still is not understood completely (Kostler, Hejna, Wenzel, & Zielinski, 2001), and data that fully characterize the impact of oral mucositis on clinical outcomes are surprisingly scarce (Trotti et al., 2003).

Cancer management, which increasingly involves the use of advanced therapeutics and aggressive antineoplastic regimens, has consequences that are favorable and unfavorable. Substantial improvements in tumor control are gained at the expense of dramatic and costly increases in oral complications, includ-

Key Points . . .

- ▶ Oral mucositis affects the majority of patients with cancer who receive stomatotoxic chemotherapy or head and neck radiation therapy or undergo blood and marrow stem cell transplant. Despite its high prevalence, the pathogenesis of oral mucositis is not completely understood.
- ▶ Recent data suggest that oral mucositis involves sequential interactions among various cells and tissue types within the oral mucosa.
- ▶ Regular use of a valid assessment tool prior to and throughout treatment can facilitate the accurate characterization of the objective and subjective manifestations of oral mucositis.
- ▶ Ultimately, the development of effective management strategies depends on a better understanding of the mechanisms that underlie the development of oral mucositis.

ing pain, ulcerations, bleeding, xerostomia (dry mouth), hypogeusia and ageusia (partial or absent taste sensations, respectively), and dysphagia (Kaplow, 2001). A multicenter study of 92 patients undergoing BMSCT found that patients having any evidence of ulceration remained in the hospital approximately 3.4 days longer and had hospital charges nearly \$43,000 higher than patients without ulceration (Sonis et al., 2001). A one-point increase in oral mucositis severity as measured by the Oral Mucositis Assessment Scale (OMAS) was associated with a \$25,000 increase in hospital charges. Other data suggest that the average cost associated with grade 3 or 4 mucositis is \$4,500, compared to \$913 for grade 1 or 2 (Smith, 2001).

Although oral mucositis clearly affects patients' experiences as well as treatment course, the paucity of outcomes data supports the viewpoint that this toxicity is an inevitable rather than a preventable complication (Trotti et al., 2003). The development of effective management strategies ultimately relies on a better understanding of the mechanisms that

Marylin J. Dodd, RN, PhD, FAAN, is an associate dean in the School of Nursing, a professor in the Department of Physiological Nursing, and director of the Center for Symptom Management in the School of Nursing, all at the University of California, San Francisco. (Submitted December 2003. Accepted for publication April 2, 2004.)

Digital Object Identifier: 10.1188/04.ONF.S4.5-11

underlie the development of oral mucositis coupled with the systematic use of measures to assess at-risk patients so that therapy can be individualized.

Novel Pathways and Mechanisms for Oral Mucositis

Mucositis is a general term for the erythematous, erosive, inflammatory, and ulcerative lesions that occur in the mucosal lining of the mouth, pharynx, esophagus, and entire gastrointestinal tract secondary to cytotoxic cancer therapy (Peterson, 1999; Shih, Miaskowski, Dodd, Stotts, & MacPhail, 2003; Squier & Kremer, 2001). Oral mucositis occurs solely in the oropharyngeal cavity.

The oropharyngeal mucosa, which is comprised primarily of stratified, squamous, nonkeratinizing epithelium that protects the underlying fibrous connective tissue and organs against mechanical and chemical assault, tends to bear the brunt of the effects of cancer therapy (Squier & Kremer, 2001). These cells are especially vulnerable to the cytotoxic or proliferative-limiting effects of stomatotoxic chemotherapy and head and neck radiation therapy because of their high turnover rates (i.e., the cells live for approximately 3–5 days and the epithelium is completely replaced every 7–14 days) (Shih et al., 2003). In patients who receive head and neck radiation therapy, ulcerative, inflammatory changes typically involve the nonkeratinized epithelium of the floor of the mouth, bilateral buccal regions, tongue, and soft palate. In patients undergoing BMSCT, the most prominent lesions can be observed within the direct portals of radiation (Peterson, 1999). Rarely affected are those areas in the mouth with slower cell turnover (i.e., the gingiva, dorsal surface of the tongue, and hard palate).

Until recently, oral mucositis was thought to develop solely from the direct toxic effects of radiation therapy or chemotherapy on epithelial cells (Sonis et al., 2000). However, evidence suggests that oral mucositis is more biologically complex than originally suspected, involving a sequential interaction of all cells and tissue types and various physiologic elements (e.g., tissue factors, cytokines) that comprise the oral mucosa (Sonis et al., 2002). Importantly, mucositis is a multiphase process rather than a single event (Eilers, 2001) that varies depending on the type and characteristics of treatment received (see Table 1).

Phase I is the inflammatory or vascular phase that occurs shortly after administration of cancer treatment. The resultant insult generates reactive oxygen species (ROS), which are normal byproducts of cellular metabolism, within the cells that comprise the epithelium (Sonis, 2003). When injury occurs, the body's ability to neutralize ROS is overwhelmed and the risk for significant damage is increased. Concurrently, cytokines, including tumor necrosis factor- α (TNF- α), interleukin- (IL-) 1, IL-1b, and IL-6, are released (see Figure 1). Although the role of the immune system in the pathogenesis of oral mucositis is unclear, data suggest that simultaneous release of IL-11 during phase I may help to attenuate proinflammatory cytokine expression and maintain the function and differentiation of mucosal cells, thereby protecting underlying connective tissue (Sonis et al., 2000).

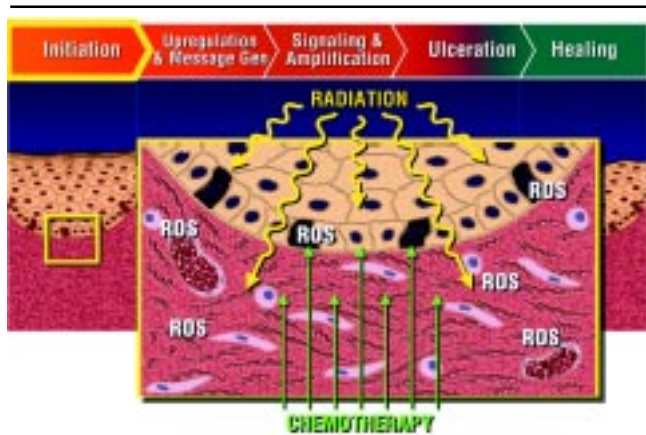
Phase II, the epithelial phase, probably is the best documented and most profound in terms of the production of ulcerative lesions (Sonis, 1998). This phase involves simultaneous biologic events in all tissues and at all levels of the epithelium, leading to a generalized alteration in the mucosal environment. Concurrent with the flood of locally produced cytokines that amplify tissue destruction (Sonis, 1998) is the rapid expression of transcription factors (e.g., nuclear factor-kappa B) that modify and speed up the genetic expression of cytokines and enzymes critical to the processes of apoptosis (i.e., cellular death) and tissue damage (Sonis, 2003; Sonis et al., 2002) (see Figure 2). Elevated endogenous concentrations of the cytokines TNF- α and IL-6 in patients undergoing BMSCT have been linked with major treatment-related complications (Hall, Benko, Hogan, & Stuart, 1995; Rabinowitz, Petros, Stuart, & Peters, 1993). Therefore, genetic polymorphisms in the expression of transcription factors and their subsequent influence on these cytokines and others may partially explain individual patient differences in oral mucositis severity during this phase (Kostler et al., 2001).

Apoptosis is functionally significant in the pathogenesis of oral mucositis, and the sphingomyelin pathway, a signaling pathway mediating the actions of the cytokines TNF- α and IL-1, appears to play an essential role (Kanety, Hem, Papa, & Karasik, 1996; Sonis, O'Donnell, Popat, & Hwang, 2003). Recent data suggest that the development of oral mucositis is mediated partially by the sphingomyelin pathway via ceramide synthase, a metabolite of ceramide, which acts as a second messenger and is involved in stress-associated apoptosis

Table 1. Patterns of Oral Mucositis

Treatment Modality	Disease Pattern or Course	Treatment-Related Confounding Factors
Chemotherapy (multiple-agent protocols)	Based on typical 21–28 day cycle: From day 4–5, patients experience clinically evident oral mucositis; from day 6–12, symptoms peak; and from day 12–16, healing occurs.	Agent, therapeutic regimen, duration or intensity, previous treatment, concomitant treatment, impaired renal function
Head and neck radiation therapy followed by concomitant stomatotoxic chemotherapy	Week 2 of radiation therapy: Patients experience clinically evident oral mucositis. From week 5–6 of radiation therapy, symptoms peak and may last several weeks following radiation therapy.	Type of radiation, total dose, depth of penetration, field size or fractionation, concurrent chemotherapy dose schedule, oral tumors
Blood and marrow stem cell transplant	From day 3–10 following conditioning, patients experience clinically evident oral mucositis. On days 7–11 after the final dose, symptoms peak and may last up to two to three weeks unless complicated by post-transplant immunosuppressive disease or graft-versus-host disease.	Pretransplant immunosuppressive therapy, prolonged immunosuppressive therapy post-treatment

Note. Based on information from Beck, 1999; McGuire, 2002; Sonis, 1998.



Gen—generation; ROS—reactive oxygen series

Figure 1. Phase I: The Inflammatory or Vascular Phase

Note. From “The Pathobiology of Mucositis” by S.T. Sonis at the annual meeting of the American Society of Clinical Oncology, Chicago, IL, June 2003. Reprinted with the permission of S.T. Sonis.

(Kolesnick, 2002; Sonis et al., 2003). Since the 1990s, interest has grown in the potential for manipulating levels of ceramide to enhance cancer therapies. Ultimately, killing tumor cells may be possible by increasing their ceramide content, thereby preventing oral mucositis (Kolesnick).

Phase III, the ulcerative phase, may be the most symptomatic and biologically complex phase and the time during which oral mucositis most significantly influences a patient’s well-being (Sonis, 1998). The severity of ulceration increases over time and peaks during the white blood cell nadir (Sonis, 1998). Bacterial colonization provides a source for cellular wall products,

including endotoxin, that facilitate a burst of macrophages causing the further release of cytokines (Sonis, 1998). Not only is local mucosal injury amplified, but the risk for secondary infections (e.g., bacteremia, sepsis) also increases (see Figure 3).

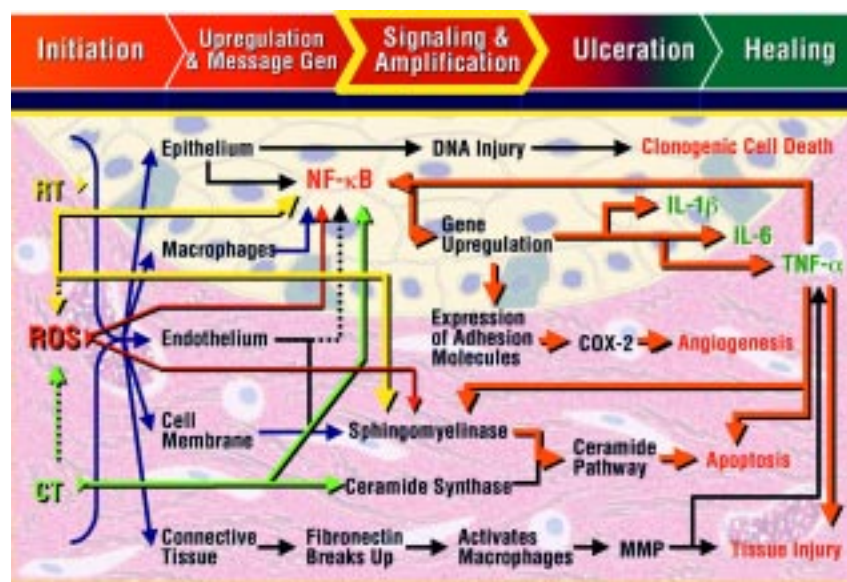
Phase IV, the healing phase, primarily focuses on cell proliferation and differentiation to restore the epithelium, normalize peripheral white cells, and control bacterial flora. Although the tissue appears normal during this phase, it is not; this is because the numerous changes that occurred at the molecular and cellular levels persist (see Figure 4). The rapidity with which healing occurs is influenced by factors that interfere with wound healing, such as infection, mechanical irritation (Kostler et al., 2001), and repeated cycles of chemotherapy.

Patterns and Risks of Oral Mucositis

Accurate determination of the incidence and prevalence of oral mucositis is difficult (Eilers, 2001). Some patients with cancer never develop oral mucositis with their therapy, and not every treatment causes oral mucositis. Moreover, many patients receive multiple treatments over time, meaning that although one specific therapeutic component might cause oral mucositis, another might not. Nevertheless, researchers generally agree that the frequency of oral complications associated with aggressive cancer treatments ranges from an estimated 40% of patients receiving primary chemotherapy to 80% of patients undergoing BMST and 100% of patients receiving radiation therapy (especially concurrent chemotherapy and hyperfractionated radiation therapy) to fields involving the oral cavity (NCI, 2003).

Radiation Therapy

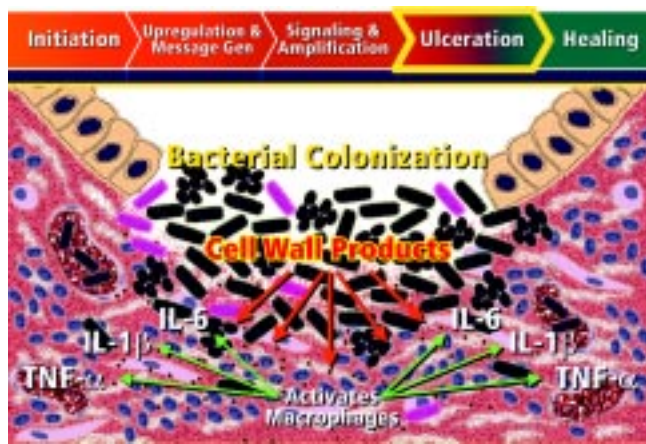
Patterns of oral mucositis vary with the type of antineoplastic treatment. Certain treatment-related factors also play a role in altering the time course for oral mucositis. For example, the degree and duration of oral mucositis in patients who receive head and neck radiation therapy are influenced by the radiation source, cumulative dose, dose intensity, and volume of radiated tissue or fractionation (Kostler et al., 2001; NCI, 2003). Patients who receive head and neck radiation therapy tend to develop erythema during the second week of therapy in conjunction with a total dose of approximately 2,000 cGY (Shih et al., 2003), and symptoms peak around the fifth or sixth week of radiation therapy. Severity increases as the dose increases, with the worst mucosal reactions associated with total doses ranging from 5,000–6,000 cGY (Shih et al.). Data from a recent meta-analysis (33 studies enrolling 6,181 patients receiving head and neck radiation therapy) demonstrated that hyperfractionation also influences severity; 56% of patients who received altered fractionation radiation therapy had grade 3–4 mucositis, compared with 34% of patients who received conventional radiation therapy (Trotti et al., 2003). Likewise, concurrent chemotherapy increases the prevalence of severe mucositis from an estimated 60% up to 100% (Shih et al.). Tissues with a large blood supply or high cell turnover rate (e.g., areas



COX-2—cyclooxygenase-2; CT—chemotherapy; Gen—generation; IL—interleukin; MMP—matrix metalloproteinase; NF-κB—nuclear factor-kappa B; ROS—reactive oxygen species; RT—radiation therapy; TNF-α—tumor necrosis factor-α

Figure 2. Phase II: The Epithelial Phase

Note. From “The Pathobiology of Mucositis” by S.T. Sonis at the annual meeting of the American Society of Clinical Oncology, Chicago, IL, June 2003. Reprinted with the permission of S.T. Sonis.



Gen—generation; IL—interleukin; TNF- α —tumor necrosis factor- α

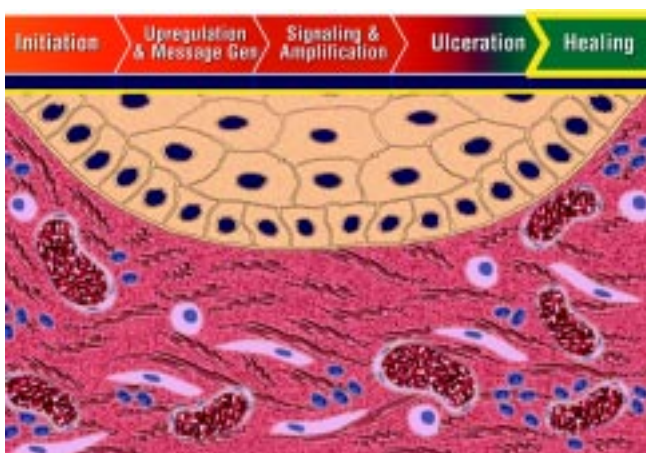Figure 3. Phase III: The Ulcerative Phase

Note. From “The Pathobiology of Mucositis” by S.T. Sonis at the annual meeting of the American Society of Clinical Oncology, Chicago, IL, June 2003. Reprinted with the permission of S.T. Sonis.

with lateral borders, ventral surface of the tongue, floor of the mouth) also tend to respond more intensely to radiation therapy (Shih et al.). Radiation therapy not only causes permanent tissue damage but also can induce functional and physical damage to the vasculature, salivary glands, muscle, and bone that subsequently increases the risk for chronic sequelae. Salivary secretions in particular tend to decrease dramatically in the irradiated field. The association between xerostomia and increased risk for oral mucositis is attributed to the decreased production and reduced buffering capacity of saliva, an increase in its acidity and viscosity, and reduced immunoglobulin A levels, which favors the growth of cariogenic and infectious oral flora (Kostler et al.).

Stomatotoxic Chemotherapy

Among patients who receive chemotherapy, damage tends to occur within four to five days after the administration of che-



Gen—generation

Figure 4. Phase IV: The Healing Phase

Note. From “The Pathobiology of Mucositis” by S.T. Sonis at the annual meeting of the American Society of Clinical Oncology, Chicago, IL, June 2003. Reprinted with the permission of S.T. Sonis.

Alkylating agents

Busulfan^a
Cyclophosphamide^a
Mechlorethamine^a
Procarbazine
Thiotepa^b
Melphalan

Anthracyclines

Daunorubicin
Doxorubicin
Epirubicin
Doxil^a

Antimetabolites

Cytosine arabinoside
5-fluorouracil^a
High-dose methotrexate^a
6-mercaptopurine
6-thioguanine
Capecitabine^a
Floxuridine

Antitumor antibiotics

Actinomycin D
Bleomycin
Daunomycin
Etoposide
Mitoxantrone
Mithramycin
Mitomycin

Taxanes

Paclitaxel
Docetaxel

Vinca alkaloids

Vinblastine
Vinorelbine

Miscellaneous

Etoposide
Hydroxyurea

Figure 5. Mucositis-Producing Chemotherapeutic Agents by Class

^a Most commonly implicated

^b Only problematic in combination with other agents or in high doses

Note. Based on information from Wilkes, 1998.

motherapy. However, not all chemotherapy drugs cause oral mucositis. Therefore, nurses need to evaluate patients' chemotherapy regimen and determine whether they are at risk for the development of oral mucositis (see Figure 5). Although agents with the highest stomatotoxic potential typically affect DNA

Table 2. Oral Complications of Cancer Therapy

Complication	Impact
Xerostomia	Progressive, sometimes irreversible, more than 95% decline in salivary function following three years of radiation therapy (Beck, 1999; Shih et al., 2003); overabundance of thick mucous, diminished lubrication; loss of desire for food can lead to nutritional deficits and malnutrition; contributes to dental caries and progressive periodontal disease (National Cancer Institute, 2003)
Hypogeusia or ageusia	Hypogeusia reduces people's ability to taste. Ageusia results in the inability to taste sweet, sour, bitter, or salty substances (Shih et al., 2003).
Dysphagia	Related to pain and swelling of affected nasopharyngeal tissues
Pain	Can cause significant difficulties in swallowing, chewing, or eating, which can lead to nutritional deficits and malnutrition; may be intensified by swallowing or speaking (Shih et al., 2003); significantly affects quality of life
Infection (viral, bacterial, fungal)	Bacterial infections are common and primarily affect gingiva, oral mucosa, and teeth; 25%–64% of identifiable causes of septicemia in patients with cancer originate in the mouth (Shih et al., 2003). May worsen existing mucosal injury or increase susceptibility to infection by other organisms (McGuire et al., 2002); systemic infections tend to occur in more intensely treated patients in relation to regimens that cause greater degrees of mucosal injury (Khan & Wingard, 2001).

synthesis (S phase of the cell cycle), such as 5-fluorouracil, methotrexate, and cytarabine (Sonis, 1998), the risk for oral mucositis is difficult to predict strictly on the basis of drug class (NCI, 2003). Moreover, data are lacking with regard to the cumulative toxic effect of multiple-agent regimens (Eilers, 2001). However, the dose, intensity, duration, and frequency of chemotherapy administration increase the risk for oral mucositis. Among patients receiving stomatotoxic chemotherapy who develop oral mucositis, ulceration tends to become clinically apparent about one week after treatment and severity generally progresses to a nadir roughly 14 days after the start of therapy and three to four days after oral mucositis peaks (Sonis, 1998).

Blood and Marrow Stem Cell Transplant

Oral mucositis in patients undergoing BMSCT typically is related to the aggressive and synergistic nature of pretreatment therapies (Beck, 1999). Most patients experience symptoms 3–10 days after treatment, which usually peak at 1–1.5 weeks. Oral complications have been linked to post-transplant immunosuppressive therapy and the development of graft-versus-host disease (Beck). Bacterial, fungal, and viral infections are common, but xerostomia, which often is present throughout the post-transplant period, also increases the risk for infection (Beck).

Patient-Specific Risk Factors

Data are conflicting, but the overall frequency and severity of oral mucositis appear to be influenced by patient-specific

factors (Sonis, 1998), including age (younger patients develop oral mucositis more frequently than those 65 years of age or older but heal more quickly), diagnosis (hematologic malignancies more often are associated with lesions than solid tumors), and oral health status (poor oral or dental health contributes to a greater likelihood of oral problems following treatment) (Eilers, 2001; Sonis, 1998). Other risk factors include previous cancer treatment, concomitant trauma from ill-fitting prostheses, jagged teeth, harsh foods, alcohol use, defects in certain metabolic enzymes (e.g., dihydropyrimidine dehydrogenase) (Kostler et al., 2001), and coexisting illness (e.g., diabetes, AIDS) (Eilers).

Secondary Oral Complications

In addition to xerostomia, oral complications associated with cancer therapy and oral mucositis may include changes in the quality of saliva (e.g., a decline in production of glycoproteins and salivary pH that render epithelial cells more vulnerable to irritation, trauma, and infectious alterations) (Shih et al., 2003), taste changes, and pain. Taste buds are especially sensitive to radiation, and patients may develop hypogeusia or ageusia during treatment (Shih et al.). Regardless of its duration (taste sensation usually is regained 6–12 months after treatment is completed), taste alterations, coupled with xerostomia, pain, and dysphagia, are associated with a loss of pleasure or interest in eating, compromised nutritional status, and malnutrition (Shih et al.) (see Table 2).

	Labial Mucosa		Buccal Mucosa		Tongue			Floor of Mouth	Soft Palate
	Lower	Upper	R	L	Dorsal	Lateral	Ventral		
Atrophy									
Erythema									
Edema									
Ulcer/Pseudomembrane (measure in cm)									

R = Patient's right L = Patient's left

Comments:

Total Score _____

Instructions for grading: Each box must have a number.

Record 00 to 03 in each box based on the following criteria:

Dorsal tongue atrophy: scored from "normal" length of filiform papilla to grade 3 (total loss of normal architecture i.e., bald tongue) (00 = normal, 01 = mild atrophy, 02 = moderate atrophy, 03 = severe atrophy)

Erythema: scored from "normal" redness for a site to grade 3 (color of fresh, oxygenated red blood) (00 = normal, 01 = mild atrophy, 02 = moderate atrophy, 03 = severe atrophy)

Lateral tongue edema: scored from "normal" to grade 03 (tongue indented s/p pressure of teeth, and "fills" the oral cavity to palate) (00 = normal, 01 = mild atrophy, 02 = moderate atrophy, 03 = severe atrophy)

Ulceration/Pseudomembrane: Surface area of involvement for each site

00 = no ulceration/pseudomembrane

01 = > 0 cm² but < 1 cm²

02 = ≥ 1 cm² but < 2 cm²

03 = ≥ 2 cm²

s/p—status post

Figure 6. Oral Mucositis Index

Note. From "The 20 Item Oral Mucositis Index: Reliability and Validity in Bone Marrow and Stem Cell Transplant Patients" by D.B. McGuire, D.E. Peterson, S. Muller, D.C. Owen, M.F. Slemmons, and M.M. Schubert, 2002, *Cancer Investigation*, 20, p. 895. Copyright 2002 by Marcel Dekker, Inc. Reprinted with permission.

Characterization of Mucositis: Setting the Stage for Prevention and Treatment

Clinical measures are essential for the effective management of oral mucositis. Regular use of a valid assessment tool prior to and throughout treatment can help to ensure that changes in the oral cavity are addressed as they arise (Eilers, 2001). However, a major impediment to the assessment of oral mucositis in research and clinical practice has been the lack of accepted, validated, scoring systems (Sonis et al., 1999) that comprehensively capture objective and subjective characteristics of oral mucositis. This is especially relevant because oral mucositis is a disease with diverse characteristics that typically vary among patients (e.g., ulceration [objective], pain [subjective], inability to eat [functional]). Additionally, commonly used tools fail to provide precise measures of tissue injury.

Many assessment tools used in clinical practice have their basis in research. One of the more recently developed instruments, the 20-item Oral Mucositis Index (OMI), is an objective measure of the degree of oral tissue injury (McGuire et al., 2002) (see Figure 6). This instrument rates four types of changes in nine anatomic areas. The upper and lower labial mucosa, right and left buccal mucosa, the floor of the mouth, the soft palate, and the dorsal, lateral, and ventral tongue each are evaluated separately for erythema, ulceration, or a pseudomembrane. The dorsal tongue also is examined for atrophy and the lateral tongue for edema. All items are scored from 0 (none) to 3 (severe), for a possible composite score of 0–60. Subscale scores, ranging from 0–27, can be calculated for erythema and ulceration separately. The OMI is able to measure the changes associated with mucositis as it develops

and resolves. This is an important feature considering that differences in treatment regimens and other factors lead to a high degree of variability in the incidence, severity, and patterns of mucositis. The OMI is reliable and valid, but it is exclusively a quantifiable measure of the degree of oral tissue injury and does not offer any functional or subjective outcomes data.

The OMAS fills this information gap by combining objective measures of lesion severity with subjective patient ratings of mouth pain and swallowing. Degrees of ulceration and erythema are measured in nine anatomic sites (upper and lower lip, right and left cheek, right and left ventral and lateral tongue, floor of mouth, soft palate or fauces, hard palate). Ulceration is scored on a scale from 0–3, depending on level of surface area involvement (0 = no lesion, 1 = < 1 cm², 2 = 1–3 cm², 3 = > 3 cm²), and erythema is rated by severity on a scale from 0–2 (0 = none, 1 = not severe, 2 = severe). Patients indicate their level of mouth pain and swallowing ability using a visual analog scale (Sonis et al., 1999). The OMAS is easy to use, reproducible, and responsive to clinically important changes in oral mucositis over time.

No tool is used more widely in clinical practice than the Oral Assessment Guide (OAG), largely because of its simplicity, reliability, and reproducibility (see Table 3). This eight-item tool assesses a patient's oral cavity and functional status with a numerical scale ranging from 1–3, which corresponds to descriptive ratings in each category (Eilers, Berger, & Petersen, 1988). The OAG gives specific instructions for obtaining measurements in each category. For example, saliva is scored by inserting a tongue blade into the mouth, touching the center of the tongue and the floor of the mouth, and assigning a rating of 1–3 (1 = watery, 2 = thick or ropy, 3 = absent). To

Table 3. Oral Assessment Guide

Category	Tools for Assessment	Methods of Measurement	Numerical and Descriptive Ratings		
			1	2	3
Voice	Auditory	Converse with patient.	Normal	Deeper or raspy	Difficulty talking or painful
Swallow	Observation	Ask patient to swallow. To test gag reflex, gently place blade on back of tongue and depress.	Normal swallow	Some pain on swallowing	Unable to swallow
Lips	Visual/palpatory	Observe and feel tissue.	Smooth and pink and moist	Dry or cracked	Ulcerated or bleeding
Tongue	Visual/palpatory	Feel and observe appearance of tissue.	Pink and moist and papillae present	Coated or loss of papillae with a shiny appearance with or without redness	Blistered or cracked
Saliva	Tongue blade	Insert blade into mouth, touching the center of the tongue and the floor of the mouth.	Watery	Thick or ropy	Absent
Mucous membranes	Visual	Observe appearance of tissue.	Pink and moist	Reddened or coated (increased whiteness) without ulcerations	Ulcerations with or without bleeding
Gingiva	Tongue blade and visual	Gently press tissue with tip of blade.	Pink and stippled and firm	Edematous with or without redness	Spontaneous bleeding or bleeding with pressure
Teeth or dentures (or denture-bearing area)	Visual	Observe appearance of teeth or denture-bearing area.	Clean and no debris	Plaque or debris in localized areas (between teeth if present)	Plaque or debris generalized along gum line or denture-bearing area

© J. Eilers, 1983. Reprinted with permission.

evaluate voice, the caregiver is asked to converse with the patient and assign a rating of 1–3 (1 = normal, 2 = deeper or raspy, 3 = difficulty talking or painful). The dual nature of the OAG not only facilitates knowledge about physical impairment and alteration of the oral cavity but fosters a better understanding of how overall patient well-being may be affected by oral mucositis. The OAG is simple enough that patients and family caregivers may be taught to use it for self-assessment purposes.

The NCI's (1998) Common Toxicity Criteria (CTC), a system developed to standardize reporting of adverse events that occur in cancer trials, is an instrument that can be used adjunctively to monitor changes in the severity of mucositis. A small portion of the CTC focuses on mucositis, which is graded on a scale of 0 (none) to 4 (life-threatening or disabling event). Although mucositis resulting from head and neck radiation therapy has its own category, mucositis not caused by radiation therapy is graded in the gastrointestinal category for specific cancer sites. Scales such as the CTC are only gross indicators of the degree of toxicity (Beck, 1999) and as such may not be as useful as other, more specific assessment tools for the management of oral mucositis.

Although researchers have not yet fully elucidated the underlying mechanisms of oral mucositis, accumulated evidence highlights the role of biologically complex interactions among all cells and tissue types, as well as cellular components and cytotoxic factors that are influenced concurrently by patient-specific factors. As understanding of this interplay increases, so will healthcare professionals' ability to identify specific therapeutic targets that may prevent the development of oral mucositis. In the interim, by acknowledging the deleterious effects that oral mucositis has on patient outcomes and quality of life, the need for oncology nurses to perform regular assessments of the oral cavity of high-risk patients becomes readily apparent. The use of standardized assessment tools to better characterize the objective and subjective components of oral mucositis will lead to prompt recognition of and appropriate treatments for this common problem associated with cancer treatment.

Author Contact: Marylin J. Dodd, RN, PhD, FAAN, can be reached at marylin.dodd@nursing.ucsf.edu, with copy to editor at rose_mary@earthlink.net.

References

- Beck, S.L. (1999). Mucositis. In C.H. Yarbro, M.H. Frogge, & M. Goodman (Eds.), *Cancer symptom management* (2nd ed., pp. 328–343). Sudbury, MA: Jones and Bartlett.
- Eilers, J. (2001). When the mouth tells us more than it says—The impact of mucositis on quality of life. *Oncology Supportive Care Quarterly*, 1, 31–42.
- Eilers, J., Berger, A.M., & Petersen, M.C. (1988). Development, testing, and application of the Oral Assessment Guide. *Oncology Nursing Forum*, 15, 325–330.
- Hall, P.D., Benko, H., Hogan, K.R., & Stuart, R.K. (1995). The influence of serum tumor necrosis factor-alpha and interleukin-6 concentrations on nonhematologic toxicity and hematologic recovery in patients with acute myelogenous leukemia. *Experimental Hematology*, 23, 1256–1260.
- Kanety, H., Hem, R., Papa, M.Z., & Karasik, A. (1996). Sphingomyelinase and ceramide suppress insulin-induced tyrosine phosphorylation of the insulin receptor substrate-1. *Journal of Biological Chemistry*, 271, 9895–9897.
- Kaplow, R. (2001). Special nursing considerations. *Critical Care Clinics*, 17, 769–789.
- Khan, S.A., & Wingard, J.R. (2001). Infection and mucosal injury in cancer treatment. *Journal of the National Cancer Institute Monographs*, 29, 31–36.
- Kolesnick, R. (2002). The therapeutic potential of modulating the ceramide/sphingomyelin pathway. *Journal of Clinical Investigation*, 110(1), 3–8.
- Kostler, W.J., Hejna, M., Wenzel, C., & Zielinski, C.C. (2001). Oral mucositis complicating chemotherapy and/or radiotherapy options for prevention and treatment. *CA: A Cancer Journal for Clinicians*, 51, 290–315.
- McGuire, D.B. (2002). Mucosal tissue injury in cancer therapy: More than mucositis and mouthwash. *Cancer Practice*, 10, 179–191.
- McGuire, D.B., Peterson, D.E., Muller, S., Owen, D.C., Slemmons, M.F., & Schubert, M.M. (2002). The 20 item Oral Mucositis Index: Reliability and validity in bone marrow and stem cell transplant patients. *Cancer Investigation*, 20, 893–903.
- National Cancer Institute. (1998). *Cancer therapy evaluation program. Common Toxicity Criteria version 2.0*. Bethesda, MD: Author.
- National Cancer Institute. (2003). Oral complications of chemotherapy and head/neck radiation. Retrieved July 7, 2003, from <http://www.cancer.gov/cancerinfo/pdq/supportivecare/oralcomplications/HealthProfessional>
- Peterson, D.E. (1999). Research advances in oral mucositis. *Current Opinion in Oncology*, 11, 261–266.
- Pico, J.L., Avila-Garavito, A., & Naccache, P. (1998). Mucositis: Its occurrence, consequences, and treatment in the oncology setting. *Oncologist*, 3, 446–451.
- Rabinowitz, J., Petros, W.P., Stuart, A.R., & Peters, W.P. (1993). Characterization of endogenous cytokine concentrations after high-dose chemotherapy with autologous bone marrow support. *Blood*, 81, 2452–2459.
- Shih, A., Miaskowski, C., Dodd, M.J., Stotts, N.A., & MacPhail, L. (2003). Mechanisms for radiation-induced oral mucositis and the consequences. *Cancer Nursing*, 26, 222–229.
- Smith, T. (2001). Gelclair: Managing the symptoms of oral mucositis. *Hospital Medicine*, 62, 623–626.
- Sonis, S.T. (1998). Mucositis as a biological process: A new hypothesis for the development of chemotherapy-induced stomatotoxicity. *Oral Oncology*, 34(1), 39–43.
- Sonis, S.T. (2003, June). *The pathobiology of mucositis*. Paper presented at the annual meeting of the American Society of Clinical Oncology, Chicago, IL.
- Sonis, S.T., Eilers, J.P., Epstein, J.B., LeVeque, F.G., Liggett, W.H., Mullagha, M.T., et al. (1999). Validation of a new scoring system for the assessment of clinical trial research of oral mucositis induced by radiation or chemotherapy. *Cancer*, 85, 2103–2113.
- Sonis, S.T., O'Donnell, K.E., Popat, R., & Hwang, D. (2003, June). *Inhibition of ceramide synthase, but not sphingomyelinase attenuates radiation-induced mucositis in hamsters*. Paper presented at the annual meeting of the American Society of Clinical Oncology, Chicago, IL.
- Sonis, S.T., Oster, G., Fuchs, H., Bellm, L., Bradford, W.Z., Edelsberg, J., et al. (2001). Oral mucositis and the clinical and economic outcomes of hematopoietic stem-cell transplantation. *Journal of Clinical Oncology*, 19, 2201–2205.
- Sonis, S.T., Peterson, R.L., Edwards, L.J., Lucey, C.A., Wang, L., Mason, L., et al. (2000). Defining mechanisms of action of interleukin-11 on the progression of radiation-induced oral mucositis in hamsters. *Oral Oncology*, 36, 373–381.
- Sonis, S.T., Scherer, J., Phelan, S., Lucey, C.A., Barron, J.E., O'Donnell, K.E., et al. (2002). The gene expression sequence of radiated mucosa in an animal mucositis model. *Cell Proliferation*, 35(Suppl. 1), 93–102.
- Squier, C.A., & Kremer, M.J. (2001). Biology of oral mucosa and esophagus. *Journal of the National Cancer Institute Monographs*, 29, 7–15.
- Trotti, A., Bellm, L.A., Epstein, J.B., Frame, D., Fuchs, H.J., Gwede, C.K., et al. (2003). Mucositis incidence, severity, and associated outcomes in patients with head and neck cancer receiving radiotherapy with or without chemotherapy: A systematic literature review. *Radiotherapy Oncology*, 66, 253–262.
- Wilkes, J.D. (1998). Prevention and treatment of oral mucositis following cancer chemotherapy. *Seminars in Oncology*, 25, 538–551.