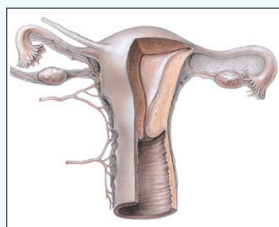


■ CNE Article/*CJON* Writing Mentorship Article

# Uterine Leiomyosarcoma: Diagnosis, Treatment, and Nursing Management

Tareai Smith, RN, BSN, OCN®, and Patricia McLaughlin, RN, MSN, AOCN®



© 2002 by Lippincott Williams and Wilkins

Uterine leiomyosarcoma is a rare form of sarcoma with limited treatment options and a high potential for distant recurrence. At the time of diagnosis, swift action should be taken to initiate treatment. Options for treatment include surgical debulking and disease staging, radiation therapy, and/or chemotherapy. The purpose of this article is to review the disease epidemiology, presentation at diagnosis, surgical staging, and prognosis. Treatment options and the role of targeted therapies are discussed in addition to the various nursing implications associated with management of the disease.

Tareai Smith, RN, BSN, OCN®, is a primary treatment nurse in the adult treatment area of the Cancer Institute of New Jersey in New Brunswick, and Patricia McLaughlin, RN, MSN, AOCN®, is a clinical research nurse with more than 25 years of oncology nursing experience. The authors take full responsibility for the content of the article. The authors were participants in the *Clinical Journal of Oncology Nursing (CJON)* Writing Mentorship Program. McLaughlin received honorarium from the Oncology Nursing Society for her role as a mentor in the *CJON* Writing Mentorship Program. The content of this article has been reviewed by independent peer reviewers to ensure that it is balanced, objective, and free from commercial bias. No financial relationships relevant to the content of this article have been disclosed by the independent peer reviewers or editorial staff. Smith can be reached at [t1.smith@comcast.net](mailto:t1.smith@comcast.net), with copy to editor at [CJONEditor@ons.org](mailto:CJONEditor@ons.org). (First submission April 2011. Revision submitted September 2011. Accepted for publication October 3, 2011.)

Digital Object Identifier:10.1188/12.CJON.267-272

Uterine sarcomas consist of a group of aggressive and rare cancers that originate from mesenchymal tissue (Lin & Slomovitz, 2008). Mesenchymal tissue is embryonic in origin and is part of the embryonic mesoderm from which blood vessels, lymphatic vessels, and connective tissue arise. Tumors from mesenchymal cells make up about 4% of uterine cancers and uterine leiomyosarcoma (LMS) accounts for about a quarter of that 4% (Bernstein-Molho, Grisaro, Soyfer, Safra, & Merimsky, 2010). Risk factors for the development of uterine LMS are not well known; however, the annual incidence is about 0.64 per 100,000 women (Zivanovic et al., 2009).

Risk factors for the development of uterine LMS are not fully understood; however, some possible risk factors include long-term use of tamoxifen, a history of pelvic irradiation, and being of African American heritage (Lin & Slomovitz, 2008). In addition, an increased incidence is noted in women aged 40–60 years (Lin & Slomovitz, 2008).

Although rare, uterine LMS may develop within a leiomyoma (Berek & Hacker, 2005). Leiomyomas are noncancerous, smooth muscle tumors that develop within the female genital tract and occur in about 40% of women older than age 40 (Al-Nafussi, 2004). Unlike uterine LMS, leiomyomas are relatively easy to diagnose pathologically and clinically (Watanabe & Suzuki, 2006). In some cases, uterine leiomyomas may transform into LMS. Yanai, Wani, Notohara, Takada, and Yoshino (2010) reported

that, despite the fact that the majority of uterine LMS tumors develop independently of preexisting abnormalities, documented cases exist of uterine LMS arising from established uterine leiomyomas. Interestingly, LMS tumor cells have been found to be within a LMS tumor. Several cellular and mitotical variations of uterine leiomyomas exist, some of which are histologically and microscopically similar to uterine LMS. For example, some benign leiomyomas exhibit microscopic characteristics that closely resemble uterine LMS, including the presence of a high mitotic index (as many as 19 mitoses per 10 high-power fields) and cellular atypia (Al-Nafussi, 2004).

Yanai et al. (2010) performed a retrospective study and found 6 of 10 cases of uterine LMS arising from leiomyomas of the broad ligament and uterus. The malignant transformation of uterine leiomyomas is more likely to occur in women ranging in age from 40–73 years. However, the prognosis for patients diagnosed with uterine LMS arising from preexisting leiomyomas is better than for patients diagnosed with primary uterine LMS (Yanai et al., 2010).

## Uterine Leiomyosarcoma

### Presentation

The typical symptoms of uterine LMS include pain, vaginal bleeding, and the presence of a pelvic mass (Giuntoli & Bristow,