



Discovering Multiple Myeloma Early in Ambulatory Patients With Chest Pain

Chao Guanqun, MD, Fang Lizheng, MD, Zang Guoyao, MD, and Colleen M. O'Leary, RN, MSN, AOCNS®

Multiple myeloma (MM) is a systemic malignancy of plasma cells often characterized by sternal, rib, or back pain. This article describes how a patient who had chest pain for more than one month was mistakenly diagnosed with reflux esophagitis. Healthcare providers should be mindful of MM when determining the source of unidentified chest pain in patients.

Chao Guanqun, MD, Fang Lizheng, MD, and Zang Guoyao, MD, all are physicians in the Department of Family Medicine in Sir Run Run Shaw Hospital at Zhejiang University in China, and Colleen M. O'Leary, RN, MSN, AOCNS®, is a clinical nurse specialist for head and neck cancer at the Ohio State University Comprehensive Cancer Center—Arthur G. James Cancer Hospital in Columbus. The authors take full responsibility for the content of the article. The authors did not receive honoraria for this work. No financial relationships relevant to the content of this article have been disclosed by the authors or editorial staff. Lizheng can be reached at lizheng.f@163.com, with copy to editor at CJONEditor@ons.org.

Digital Object Identifier: 10.1188/13.CJON.205-207

Multiple myeloma (MM) is a plasma cell neoplasm with disease usually confined to the bone marrow and occurs more often in older adults (Yasuda et al., 2010). MM usually presents with bone pain, pathologic fractures, and anemia, although the symptoms may be nonspecific; commonly reported symptoms include anemia (73%), bone pain (58%), elevated creatinine (48%), fatigue or general weakness (32%), hypercalcemia (28%), and weight loss (24%) (Kyle et al., 2003). The presence of extramedullary involvement in patients with MM is a rare clinical manifestation found in only 7% of cases and usually is associated with poor prognosis (Varettoni et al., 2010). Although MM is not difficult to confirm, providers do not routinely think of MM when a patient presents with chest pain. That can lead to a misdiagnosis or a missed diagnosis that will delay appropriate treatment for the patient.

Providers should not only have adequate knowledge of MM, but also consider this disease when treating patients in the ambulatory setting. This article presents the case of a patient who had

chest pain for more than one month and was treated for reflux esophagitis before finally being diagnosed with MM.

Background

MM is a rare postgerminal center B-cell malignancy tumor and represents almost 1% of all malignancies (Lim, Ando, Nishiyama, & Padival, 2011; Talamo, Barochia, Zangari, & Loughran, 2010). MM is a cancer of the bone marrow, also known as plasma cell myeloma or Kahler disease after Otto Kahler, MD, who first described it in 1889. This disease is clinically characterized by bone pain with lytic bone lesions and/or severe osteopenia, anemia, hypercalcemia, renal function impairment, recurrent infections, and the presence of extramedullary involvement (Moriuchi et al., 2010). Its common clinical manifestations are summarized by the acronym CRAB (hyperCalcemia, Renal insufficiency, Anemia, and Bone lesions) (International Myeloma Working Group, 2003).

Primary MM mainly is located in the bone marrow, but neoplastic cells may

invade other tissues and organs, such as the liver, lung, spleen, pancreas, kidney, and lymph nodes. The digestive tract, thyroid, heart, testis, ovary, and skin also may be involved (Wang et al., 2008). The incidence of MM is about five cases per 100,000 people per year (Landgren & Weiss, 2009). The median age of onset is 65–70 years, with one study reporting an increase of median age at diagnosis from 70–74 years since 1960 (Turesson, Velez, Kristinsson, & Landgren, 2010).

Case Study

Mr. C, a 69-year-old man, presented with more than one month's history of chest pain. He had experienced chest pain previously following chest block drainage for a pneumothorax. Mr. C has had hypertension for 12 years and had a pneumothorax twice. The current pain was described as continuous, dull,

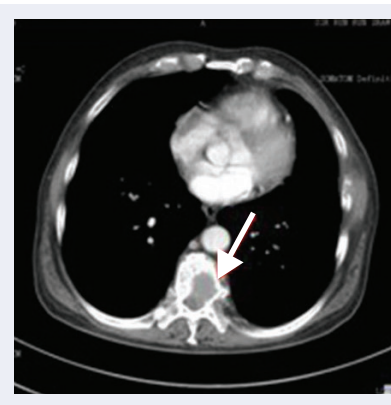


FIGURE 1. Vertebral Body of T9 Bone Substance Destroyed

Note. Image courtesy of Sir Run Run Shaw Hospital at Zhejiang University. Used with permission.